

## ACADEMIC ACCOLADES

Dr.Kailash Sarathy, Consultant Pediatric Orthopedics, won **Gold medal in TNOACON 2026, Coutrallam.**

TNOA **Prof.K.Sriram Gold Medal** for Pediatric Orthopedics for the research paper titled 'Outcomes of Foramen Magnum Decompression and Fusion for Cranio-Cervical Pathology in Morquio Syndrome - A single Centre's experience over 20 years'.



## ACADEMIC ACHIEVEMENTS

Dr Vignesh N and Dr Varshini S, final year DNB Pediatrics post graduates secured 3rd prize in the Pediatric Diabetology quiz conducted at INSPIRE 2026 on 04.01.2026

Dr.Mansi , first year DNB postgraduate won second prize in poster presentation "Rabson mendenhall syndrome - a rare cause of severe insulin resistance with long term follow up" in INSPIRE 2025 held at Apollo children's hospital, Chennai

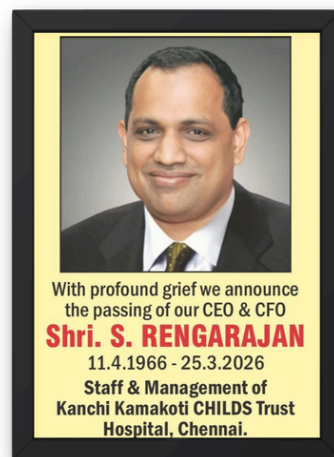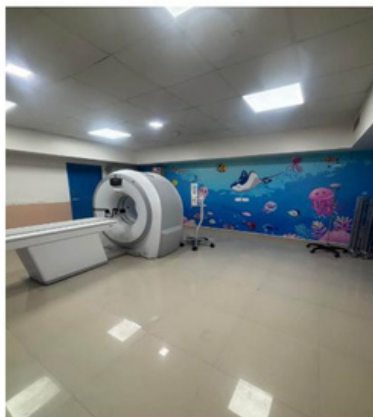Dr.Mansi , first year DNB postgraduate won second prize in oral paper presentation on "Stress-Seizure Nexus - Insights into functional neurological disorders in children" at National Pedicon 2026 , Kolkata.

Dr. Gayathri Sivakumar, PICU fellow, secured the Gold Medal in the IDPCCM Exit Examination conducted by the Indian College of Pediatric Critical care medicine held in February 2026.

Dr.Varshini.S and Dr.Anirudh won the 2nd prize in the post graduate quiz conducted by Pediatric Gastroenterology Foundation in Ped Gastro Update 2026 held at Hotel Savera, Chennai on 1st March 2026

# NEW SCOPE OF SERVICES AT KKCTH

## 32 SLICE CT SCAN MACHINE



*We dedicate our new scope of services to our esteemed former CEO, Mr.S.Rengarajan who has been great motivation and support behind our achievements.*

32 slice CT scan machine was donated by KONE and was inaugurated on March 18th by the CSR team from KONE

## SLEEP LAB LEVEL 3 AT KKCTH- DEPT OF PULMONOLOGY

We are pleased to inform you that Level 2 and Level 3 pediatric polysomnography (PSG) studies have been inaugurated from 1st of April 2026 at our center.

The lab services will be lead and guided by Dr.V.Vivekanand, Senior Consultant Pulmonologist, KKCTH. These will be overnight attended studies, supervised by our respiratory therapist, who is trained in pediatric sleep and will also function as the sleep technician during the night.

To ensure accessibility across all patient groups, we will also be introducing Level 4 studies (overnight oximetry) shortly for children who may not be able to afford Level 2 or Level 3 studies.



*Sleep Lab Level 2 was commenced from 1<sup>st</sup> of APRIL. The inauguration was done by Dr.V.V.Varadharajan, Senior Consultant Peditrician*

## MOBILE PEDIATRIC ICU AMBULANCE

SI Investments and Broking Ltd and Rotary club of Madras, donated the PICU ambulance for safe transport of critically ill children. The ambulance is well equipped with ventilator, oxygen cylinders, monitor, incubator and ultrasound machine.





## ACADEMIC ACTIVITIES



CME organised by IAP Chengelpattu - March 1st at Mahindra City was well received by the practitioners and post graduates.




CME organized by IAP Tirupathi was an interactive session with excellent feedback.



## EXCELLENCE IN PICU NURSING FELLOWSHIP

The National PICU Nursing Course exam was conducted by the Indian College of Pediatrics at several centers all over India on 8th April 2026.

Of the 47 candidates from across India, our **PICU Nurse Pavithra.R secured the Gold medal**. Nurses Kasthuri.P, Sneha.M and Gajalakshmi.P secured the 2nd, 3rd and 5th place.



## IAP PEDIATRIC SUBSPECILAITY CME AT KKCTH

**Pediatric subspecialty CME** covering relevant topics for practitioners and postgraduates was held in our hospital on 1.2.2026. Around 100 delegates attended the CME. Our DNB and DrNB postgraduates who won the **Best Outgoing Student Award** were felicitated during the inaugural ceremony.



## Leading by example!-Our Alumni Corner!

**An unusual cause of syncope – History taking in syncope revisited**  
**Dr Mani Ram Krishna and Dr Usha Nandini**  
**Interventional pediatric cardiologist**  
**Tiny Hearts Children's Hospital, Thanjavur**

A 6-year-old boy presented with recurrent syncopal episodes since infancy. He was born to third-degree consanguineous parents and had a healthy older sibling. The episodes occurred approximately once a month and were initially diagnosed as complex partial seizures. Despite treatment with multiple antiepileptic medications, there was no significant improvement. Developmental milestones were normal, and repeated EEGs, including sleep-deprived studies, were unremarkable.

A detailed history revealed that most episodes were associated with exertion. The latest episode occurred while running, during which he suddenly collapsed. His first episode was noted during bathing, preceded by crying, followed by cyanosis and limpness. Family history was significant for syncope in the mother during childhood and a maternal aunt undergoing treatment for a seizure disorder.

On examination, the child was hemodynamically stable with relative bradycardia (pulse rate 68/min). Other systemic examinations were unremarkable.



### **Investigations**

Electrocardiogram showed sinus bradycardia, normal PR interval, prolonged corrected QT interval (QTc 500 ms), and abnormal T wave morphology. These findings were suggestive of Long QT Syndrome.

Genetic testing identified a heterozygous pathogenic variant in the KCNQ1 gene, confirming the diagnosis of LQTS type 1. Family screening revealed borderline QT prolongation in the mother and brother, and significant QT prolongation in the maternal aunt.

### **Management and Outcome**

The child was initiated on beta-blocker therapy (propranolol) and later switched to a long-acting formulation. Lifestyle modifications were advised, including avoidance of QT-prolonging medications, restriction from competitive sports, and precautions during swimming. The maternal aunt was also started on beta-blocker therapy.

Over a follow-up period of two years, the child remained asymptomatic, and antiepileptic medications were discontinued.

### Table 1 – Red Flag signs to consider a cardiac cause of syncope

#### History

1. Syncope on Exertion
2. Syncope without any prodrome
3. Syncope in supine position
4. Syncope provoked by specific triggers (eg. Fever, high pitched sounds)
5. Unexplained sudden death or sudden infant death in family members
6. Unexplained drowning in family members

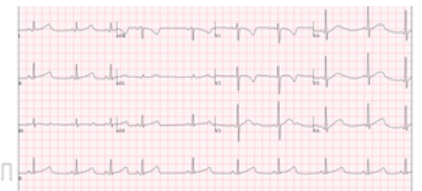


Figure 1 a- 12 lead ECG of the boy with syncope. There is relative bradycardia for age. There is sinus rhythm with normal axis and a normal PR interval. There is no bundle branch block. However, the T wave has an abnormal and markedly asymmetric morphology and the QTc interval is prolonged measuring 500 ms

# Zincovit<sup>®</sup> Syrup Drops

Zinc, Essential Vitamins & Minerals

**Zincovit CL<sup>™</sup>**  
Syrup

Multivitamin, Multimineral & Lysine

**Zincovit<sup>®</sup>**  
**ACTIVE**

Zinc, Electrolytes & Taurine  
Apple & Orange Flavour



**apex<sup>®</sup>**

apex laboratories private limited, III Floor, SIDCO Garment Complex, Guindy, Chennai - 600032, Tamil Nadu, India.  
For your feedback / queries contact: Manager - Consumer Care Cell, at Toll free No.: 1800 425 1045 from MTNL / BSNL lines. or  
e-mail: info@apexlab.com, Website: www.apexlab.com

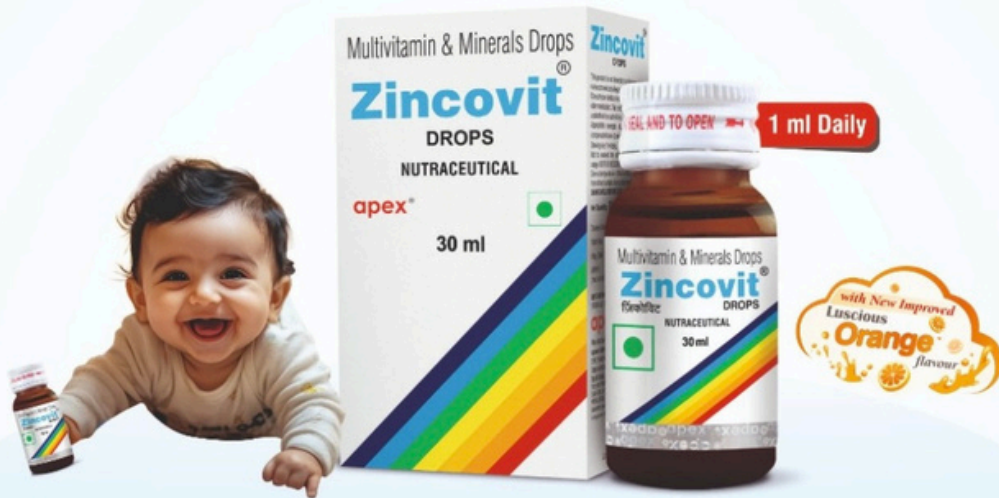For

**LONGER DURATION  
OF MICRONUTRIENT SUPPLEMENTATION**

# Zincovit<sup>®</sup>

Essential **Vitamins**, **Flaxseed Oil** with **Zinc** & **Vitamin D<sub>3</sub>** 400 IU / ml

**30 days**  
**30 ml**  
**Drops**



## Docowize<sup>®</sup> Veg

Docosahexaenoic Acid 200 mg / 5 ml

Suspension

## Trifer<sup>®</sup>

Iron (III) Hydroxide Polymaltose Complex Syrup/Drops

## Sofinox<sup>®</sup>

Sodium Fusidate 2% w/w with Cream Matrix of **BIOCHITODERM<sup>®</sup>**

**apex<sup>®</sup>**

apex laboratories private limited, III Floor, SIDCO Garment Complex, Guindy, Chennai - 600032, Tamil Nadu, India.  
For your feedback / queries contact: Manager - Consumer Care Cell, at Toll free No.: 1800 425 1045 from MTNL / BSNL lines. or  
e-mail: info@apexlab.com, Website: www.apexlab.com